www.directivepublications.org

The Journal of Anatomy

ISSN 2995-6552

Case Report

SMA with Nutcracker Syndrome and Median Arcuate Ligament Compression: A Rare Anatomical Coexistence.

Deemah Alshaya [1], Fares Alfaraj [1], Kaleemullah [1], Fahad Alabdelghani [2], Salah Termos*[1].

[1] *Department of Surgery, Amiri Hospital, MOH, Kuwait.*

[2] *Department of Radiology, Amiri Hospital, MOH, Kuwait.*

Abstract

Superior mesenteric artery (SMA) syndrome or Wilkie's syndrome is a rare cause of proximal intestinal obstruction due to compression of the third portion of the duodenum between the SMA and aorta. It can be associated with left renal vein entrapment called Nutcracker Syndrome. Median arcuate ligament (MAL) compression of the celiac trunk can further complicate the presentation. We report the case of a 17-year-old female with known SMA syndrome associated with nutcracker syndrome and radiological findings suggestive of median arcuate ligament compression. She presented with chronic postprandial abdominal pain, nausea, and significant weight loss. After failed conservative management including enteral and parenteral feeding trials, she underwent a successful laparoscopic gastrojejunostomy. Follow up revealed weight gain and improved clinical picture. This case highlights the diagnostic and therapeutic challenges in dual vascular compression syndromes.

Keywords : SMA Syndrome; Wilkie Syndrome; MALS; Nutcracker Syndrome; Gastrojejunostomy.

INTRODUCTION

The superior mesenteric artery (SMA) and celiac artery originate from the ventral segmental arteries during the 4th to 5th week of gestation. They emerge from the abdominal aorta to supply the midgut and foregut, respectively. Anatomical anomalies or severe weight loss can lead to reduce the mesenteric fat cushion causing compression symptoms. The classic presentation includes postprandial epigastric pain, early satiety, nausea, and vomiting, often leading to further weight loss and a vicious cycle [1]. Management can vary due to the etiology and associated syndromes. Surgical treatment is usually reserved after failed medical therapy.

This manuscript outlines the case of a young female patient with both SMA and MAL compression, managed successfully with simple laparoscopic gastrojejunostomy.

CASE PRESENTATION

A 17-year-old female, underweight with BMI (16.8), she was previously diagnosed with SMA syndrome was referred to our surgical unit for food phobia, persistent nausea, vomiting, abdominal pain, and a total weight loss of 25 kg over two years. Her weight had decreased from 73 to 48 kgs despite recent inpatient nutritional support. Patient had a successful attempt of weight gain of 10 kgs using parenteral and enteral feeding on a period of two weeks that was failed later due to food intolerance and eventually weight loss. This cyclical pattern indicated that conservative management alone was insufficient to sustain symptomatic or nutritional improvement.

Past Medical History : SMA with Nutcracker syndrome and MALS. Past Surgical
History : None Allergies: Metoclopramide (Primperan)
Medications : Omeprazole and Itopride.

Imaging Studies

- CT Aorta: Focal stenosis of the celiac trunk with a hooked appearance due to compression by the median arcuate ligament (**Fig 1**). Post-stenotic dilatation of hepatic and splenic arteries noted. Narrowed aorto-mesenteric angle with short

***Corresponding Author:** **Salah Termos MD, FACS,** Department of Surgery, Amiri Hospital, MOH, Kuwait. **Email:** Salahtermos@gmail.com.
Received: 09-September-2025, Manuscript No. TJOA - 5108 **; Editor Assigned:** 11-September-2025 **; Reviewed:** 25-September-2025, QC No. TJOA - 5108 **; Published:** 08-October-2025, **DOI:** 10.52338/tjoa.2025.5108.
Citation: Salah Termos MD, FACS. SMA with Nutcracker Syndrome and Median Arcuate Ligament Compression: A rare anatomical coexistence. The Journal of Anatomy. 2025 October; 13(1). doi: 10.52338/tjoa.2025.5108.
Copyright © 2025 **Salah Termos MD, FACS.** This is an open access article distributed under the Creative Commons Attribution License, which permits unrestricted use, distribution, and reproduction in any medium, provided the original work is properly cited.

segment (**Fig 2**). Persistent indentation of SMA upon left renal vein, suggesting Nutcracker syndrome (**Fig 3**).
- Upper GI Fluoroscopy: No gastroesophageal reflux or gastric outlet obstruction.
- Nuclear study: Delay gastric emptying.

Figure 1. MAL syndrome with hook sign at the CA (arrow).



Figure 2. Wilkie syndrome, narrowing of aorto-mesenteric angle.

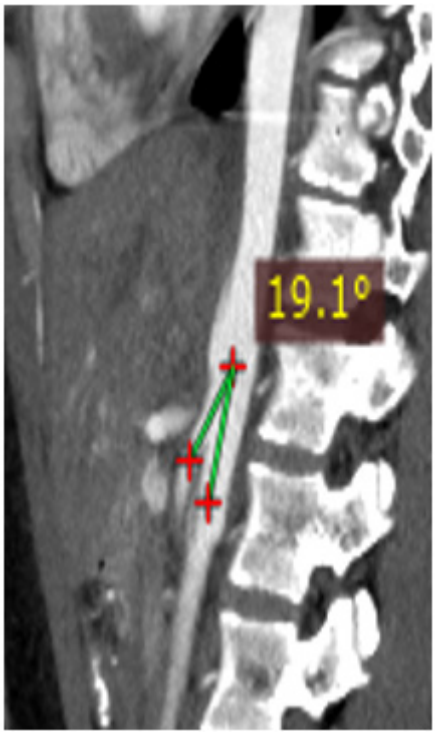

Figure 3. Nutcracker syndrome, compression of Lt renal vein (arrow).

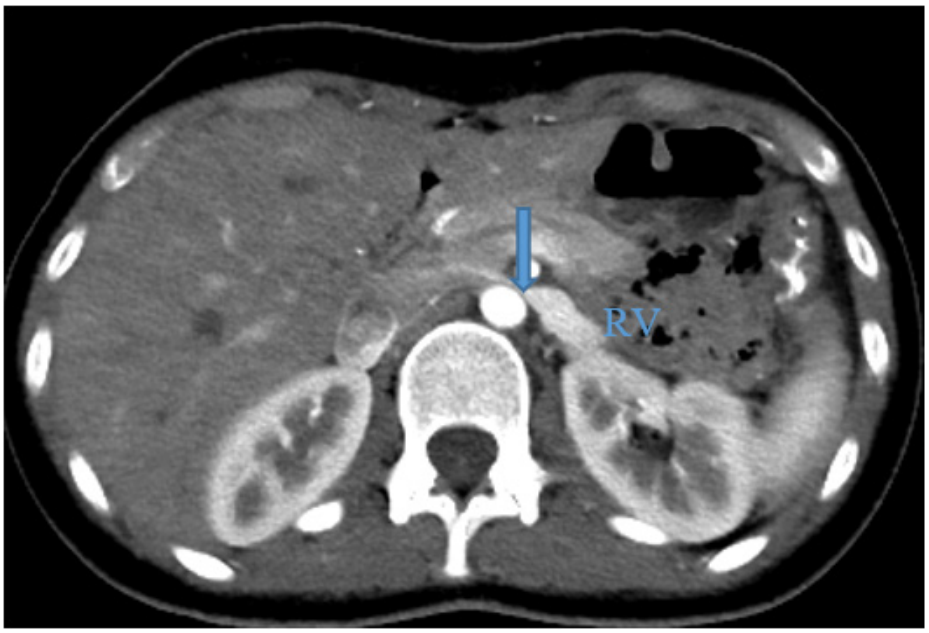

Given the persistent duodenal obstruction and delayed gastric emptying and the dual vascular compression confirmed radiologically, the decision was made to proceed with surgical intervention via laparoscopic gastrojejunostomy. Intraoperative findings showed severely distended stomach and proximal duodenum and collapsed fourth part of the duodenum and distal bowel (**Fig 4**). A laparoscopic loop gastrojejunostomy was performed with smooth postoperative period. Upper GI meal was done and revealed absence of leak and normal gastric emptying (**Fig 5**). 6 months follow up revealed good food tolerance and weight gain.

Figure 4. Intraoperative finding, dilated proximal duodenum (blue arrow) and compressed D4 and distal loops (black arrows).

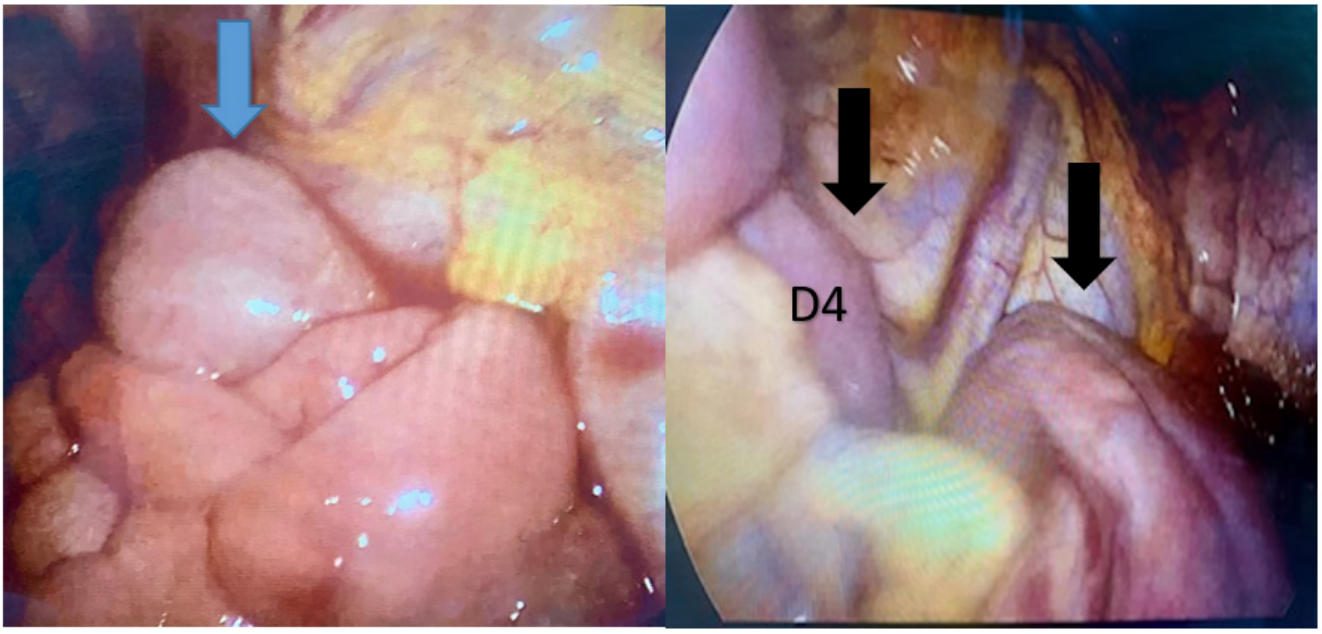

Figure 5. Water soluble swallow demonstrating prompt emyptying with no leak.



DISCUSSION

Superior Mesenteric Artery (SMA) or Wilkie's Syndrome is a rare condition caused by external compression of the third portion of the duodenum between the SMA anteriorly and the abdominal aorta posteriorly, typically due to a reduced aorto-mesenteric angle (<22°) and distance (<8–10 mm) (**Fig 6**) [2,3].

Figure 6. Wilkie syndrome with Nutcracker syndrome [3].

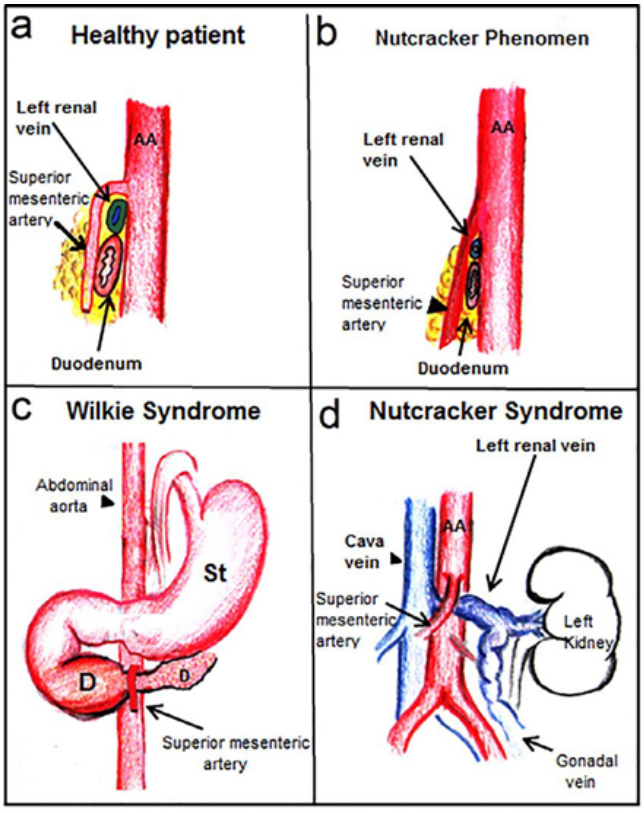

The median arcuate ligament is a fibrous arch that forms from the crura of the diaphragm and typically lies superior to the celiac artery. However, in some individuals, incomplete or altered caudal migration results in the ligament coursing lower than normal — leading to MALS due to compression of the celiac trunk. Characteristic findings include the "hooked" appearance of the celiac artery on sagittal CT angiography and dynamic changes in flow on duplex ultrasound, especially with respiration (**Fig 7**) [4,5].

Figure 7. MAL compression. [5]

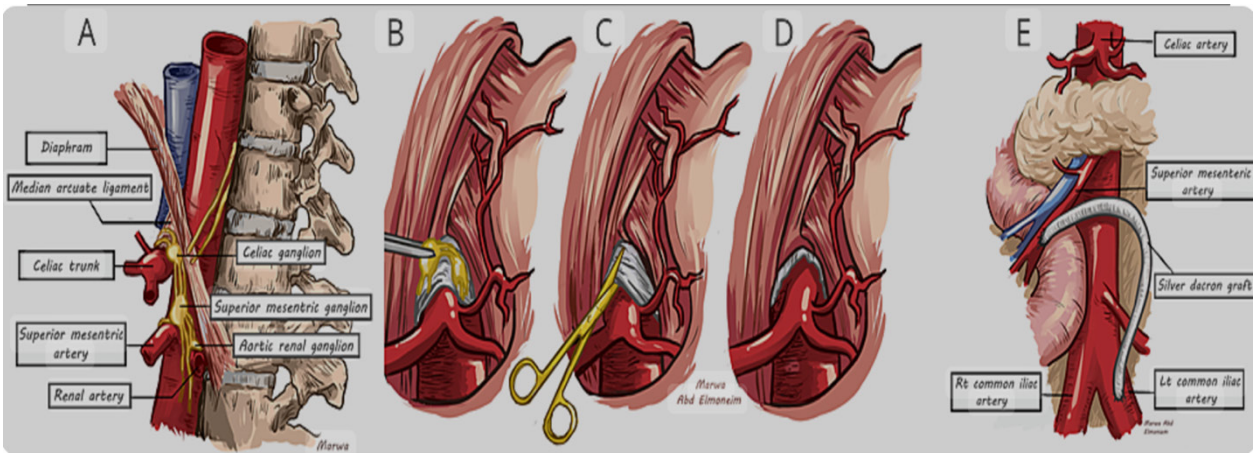

Diagnosis of both conditions relies on a combination of clinical suspicion and imaging: [4-5]

- CT Angiography (CTA) is the gold standard for defining vascular anatomy and identifying compression.
- Upper GI series can show duodenal obstruction in SMA syndrome.
- Doppler ultrasound can demonstrate elevated peak systolic velocities in the celiac artery (>200 cm/s), especially during expiration in MALS.
- Magnetic Resonance Angiography (MRA) and intravascular ultrasound (IVUS) can be useful in complex cases.

Associated anomalies for both SMA and MALS may include: [6]

- Malrotation of the gut.
- Nutcracker syndrome (compression of the left renal vein between the SMA and aorta)
- Annular pancreas (if coexisting pancreatic anomalies are present)
- Duodenal web or atresia (rare, but can present with overlapping symptoms)

In our patient, radiological findings also revealed Nutcracker Syndrome, a condition where the left renal vein is compressed between the SMA and aorta, leading to venous hypertension. Though often underdiagnosed, Nutcracker syndrome can manifest with abdominal or flank pain, hematuria, or pelvic congestion [7]. Its coexistence with SMA syndrome and Median Arcuate Ligament Syndrome (MALS) suggests a shared embryological predisposition to vascular anomalies. This rare combination creates a unique diagnostic challenge due to overlapping and compounded symptomatology.

Superior Mesenteric Artery (SMA) syndrome and Median Arcuate Ligament Syndrome (MALS) are rare vascular compression syndromes with overlapping gastrointestinal symptoms, most commonly presenting with postprandial abdominal pain, nausea, vomiting, and weight loss. Their coexistence, as seen in this case, adds significant diagnostic and therapeutic complexity.

SMA syndrome results from compression of the third portion of the duodenum between the aorta and the SMA, typically due to a narrow aortomesenteric angle and reduced retroperitoneal fat. MALS, on the other hand, involves compression of the celiac trunk by a low-lying median arcuate ligament, often resulting in foregut ischemia. In this patient, imaging demonstrated classic signs of both syndromes, including a narrowed aortomesenteric angle and a "hooked" appearance of the celiac artery, indicating dual pathology [8,9]. From an embryological standpoint, the SMA and celiac arteries originate from ventral segmental arteries, while the median arcuate ligament derives from the diaphragmatic crura. Failure of appropriate caudal migration can lead to celiac artery compression. Similarly, improper rotation or fixation of the gut may predispose to SMA syndrome. Associated anomalies, including gut malrotation and Nutcracker syndrome, may coexist, further complicating clinical presentation and management. The presence of Nutcracker Syndrome in this patient—evidenced by radiological indentation of the left renal vein—likely contributed to the overall symptom burden through renal venous congestion, potentially exacerbating pain and gastrointestinal discomfort [10]. While it was not the primary focus of intervention, its inclusion in the diagnostic workup highlights the importance of considering multiple

synchronous vascular compression syndromes. The triad of SMA syndrome, MALS, and Nutcracker represents a rare but clinically significant overlap that demands a high index of suspicion and a tailored management strategy.

Non-surgical therapeutic strategies are considered first-line for SMA syndrome and include high-calorie oral diets, postural therapy, enteral nutrition via nasojejunal feeding, and parenteral nutrition in severe cases. However, such approaches may be inadequate when anatomical compression is significant. In this case, despite inpatient nutritional support that led to temporary weight gain, the patient experienced a rapid relapse of symptoms and weight loss, highlighting failed medical management.

Surgical options become necessary when conservative therapy fails. For SMA syndrome, gastrojejunostomy or duodenojejunostomy are common procedures that bypass the obstructed segment. Strong's procedure, involving division of the ligament of Treitz, is less invasive but often insufficient alone. In cases of MALS, laparoscopic release of the median arcuate ligament is the definitive approach. However, in this patient, operative findings indicated SMA syndrome as the primary cause of obstruction [11,12].

The preferred surgical treatment for Superior Mesenteric Artery (SMA) syndrome is duodenojejunostomy, as it provides a direct bypass of the compressed third portion of the duodenum, restores near-normal physiological flow, and reduces the risk of bile reflux. However, in certain situations—such as when the duodenum is significantly fibrotic, inflamed, or technically difficult to mobilize—gastrojejunostomy becomes a viable alternative. Although less physiological, gastrojejunostomy offers a technically simpler solution with a lower risk of anastomotic tension [11]. In our case, the decision to proceed with gastrojejunostomy was based on the presence of delayed gastric emptying, family preference and intraoperative findings, including the presence of dense adhesions and limited duodenal mobility, which made a duodenojejunostomy less favorable.

CONCLUSION

Coexistence of SMA, Nutcracker and MAL syndromes is an unusual anatomic association. This case illustrates the diagnostic and therapeutic challenges posed by rare vascular anomaly. While nutritional rehabilitation remains the cornerstone of initial management, its failure necessitated surgical intervention. Ultimately, a thorough clinical evaluation and imaging studies with an individualized approach are essential to achieving optimal outcomes in such complex and overlapping conditions.

Conflict of interest

Authors declared no conflict of interest.

REFERENCES

1. Biank, V., & Werlin, S. (2006). Superior mesenteric artery syndrome in children: A 20-year experience. Journal of Pediatric Gastroenterology and Nutrition, 42(5), 522–525.
2. Dunbar, J. D., Molnar, W., Beman, F. F., & Marable, S. A. (1965). Compression of the celiac trunk and abdominal angina. American Journal of Roentgenology, 95, 731–744.
3. Farina R, Vasile T, Foti PV, et al. Wilkie Syndrome and Pseudo-Nutcracker Syndrome: a rare combination. Radiodiagnostic Unit, Catania, Italy.
4. Jimenez, J. C., Harlander-Locke, M., & Dutson, E. P. (2012). Open and laparoscopic treatment of median arcuate ligament syndrome. Journal of Vascular Surgery, 56(3), 869–873.
5. Adapted for educational use from surgical illustrations of MALS decompression, based on Holleran & Jimenez, Rutherford's Vascular Surgery and Endovascular Therapy. Cronenwett, J. L., Johnston, K. W. 9th ed., Elsevier, 2018.
6. Khandelwal, A., Fasih, N., & Kielar, A. Z. (2010). Median arcuate ligament syndrome: Evaluation with CT angiography. Radiographics, 30(2), 583–593.
7. Nijmeh Hammoud, Mariam Fadlallah,, Ali Alqattan, Salah Termos et al. Isolated symptomatic celiac artery occlusive disease in a young female. A rare clinical presentation. Acta Scientific Gastrointestinal Disorders. 2021; 85-91.
8. Lee, T. H., Lee, J. S., Jo, Y., Park, K. S., Cheon, J. H., Kim, Y. S., … & Kim, S. H. (2012). Superior mesenteric artery syndrome: Where do we stand today? Journal of Gastrointestinal Surgery, 16(12), 2203–2211.
9. Termos S, Taqi A, Hayati H, Alhasan AJMS, Alali M, Adi A. Segmental arterial mediolysis with 5 splenic artery aneurysms. A rare finding of a rare disease: Case report and literature review. Int J Surg Case Rep. 2017;33:158-162.
10. Sheehan, M., Davis, S., & Acord, M. (2013). Nutcracker syndrome and its mimics: Imaging findings and clinical considerations. AJR American Journal of Roentgenology, 200(5), W512–W520.
11. Welsch, T., Büchler, M. W., & Kienle, P. (2007). Recalling superior mesenteric artery syndrome. Digestive Surgery, 24(3), 149–156.
12. Chou, J. W., Liu, Y. H., Tiu, C. M., Chen, J. D., & Wang, J. D. (2005). Successful treatment of superior mesenteric artery syndrome with laparoscopic duodenojejunostomy. Journal of the Formosan Medical Association, 104(3), 234–237.