www.directivepublications.org

The Journal of Clinical Medicine

ISSN 2995-6315

Case Series

Myasthenia Gravis- Same Disease Yet Not Similar- A Case Series.

Dr Priyanka V Kashyap[1], Dr Vaibhav O P Pandey[2], Dr Naman Sahu[3]

[1]*Associate Professor, Department of Neurology, AIIMS, Bhopal;462026.*
[2]*Senior Resident, Department of Neurology, AIIMS, Bhopal;462026.*
[3]*Senior Resident, Department of Neurology, AIIMS, Bhopal;462026.*

Abstract

Introduction: Myasthenia gravis (MG) and related myasthenic syndromes show striking heterogeneity in phenotype, investigations, and treatment response, often complicating timely diagnosis and individualized management. We describe a series of four patients with myasthenic syndromes evaluated at AIIMS Bhopal, highlighting clinical presentation, key diagnostic work-up (including antibody testing, neurophysiology, neuroimaging, and next-generation sequencing when indicated), treatment strategies, and short-term outcomes.
Case Reports: One acetylcholine receptor antibody–positive generalized MG patient developed impending myasthenic crisis precipitated by infection and suboptimal pyridostigmine dosing, improving with optimized anticholinesterase therapy, ventilatory support, intravenous immunoglobulin, and rituximab. A second patient with smoldering childhood onset ocular weakness with family history decoded at sixth decade. A third patient unveils approaching a chronic progressive external ophthalmoplegia (CPEO) phenotype. The fourth, an AChR-positive MG patient prenting with sudden hemiparesis and how we approached.
Conclusion This series underscores that ostensibly similar "myasthenic" presentations can reflect diverse autoimmune, genetic, and structural etiologies, and that meticulous clinical assessment, rational use of electrophysiology and genomics, and context-sensitive therapeutic tailoring are crucial for optimal outcomes.

Keywords: Myasthenia Gravis, Myasthenic crisis, Congenital Myasthenic Syndrome, Glioma.

INTRODUCTION

Myasthenia Gravis (MG) is a chronic autoimmune neuromuscular disorder characterized by fluctuating skeletal muscle weakness and fatiguability [1]. The disease most commonly results from autoantibodies directed against components of the postsynaptic neuromuscular junction, particularly the acetylcholine receptor (AChR) or, less commonly, muscle-specific kinase (MuSK) [2]. MG has a broad clinical spectrum, ranging from isolated ocular involvement to life-threatening generalized weakness affecting bulbar and respiratory muscles, leading to myasthenic crisis. Despite advances in diagnostic modalities and immunotherapy, MG continues to present diagnostic and therapeutic challenges, particularly in atypical presentations or treatment-refractory cases [3]. Early recognition, appropriate use of pharmacologic testing, antibody assays, and electrophysiological studies, alongside genetic testing when indicated, are critical for timely diagnosis and management. Additionally, individualized treatment plans- including anticholinesterase agents, corticosteroids, immuno-modulators, IVIG (Intravenous Immunoglobulin), plasmapharesis, and targeted therapies such as Rituximab- can significantly improve patient outcomes [4]. This case series highlights the diverse clinical presentations, diagnostic complexities, and varied treatment responses seen in MG. It includes cases of generalized MG with crisis, congenital myasthenic syndrome, and diagnostic dilemmas involving overlapping features with mitochondrial and inflammatory disorders. This series aims to bring a tailored, multidisciplinary approach in the management of myasthenic syndromes. Varied and rare case scenarios and focused key points that helped in managing odd MG cases are highlighted here.

CASE PRESENTATIONS

Case 1: Unfolding frequent Myasthenic Crisis in AChR-Positive Generalized Myasthenia Gravis

A middle-aged gentleman diagnosed with acetylcholine

***Corresponding Author:** Dr. Priyanka V Kashyap.* Associate Professor Neurology AIIMS Bhopal. **Email:** dr_pvinod@yahoo.co.in.
Received: 25-Mar-2026, Manuscript No. TJOCM - 5536 **; Editor Assigned:** 25-Mar-2026 **; Reviewed:** 20-Apr-2026, QC No. TJOCM - 5536 **; Published:** 30-Apr-2026.
DOI: 10.52338/tjocm.2026.5536.
Citation: Dr. Priyanka V Kashyap. Myasthenia Gravis- Same Disease Yet Not Similar- A Case Series. The Journal of Clinical Medicine. 2026 April; 16(1). doi: 10.52338/tjocm.2026.5536.
Copyright © 2026 **Dr. Priyanka V Kashyap.** This is an open access article distributed under the Creative Commons Attribution License, which permits unrestricted use, distribution, and reproduction in any medium, provided the original work is properly cited.

receptor (AChR) antibody-positive generalized Myasthenia Gravis (MG) for 1.5 years presented with bulbo-respiratory symptoms in form of progressive orthopnea, dysphagia, and nasality in speech of a week's duration. On detailed questioning, he reported never taking optimized dosage and also, never achieved complete remission of his symptoms. He reported missing pyridostigmine for three consecutive days prior to symptom onset and had lower respiratory tract infection (LRTI) for which he probably received MG triggering antibiotics. On admission to AIIMS Bhopal, his Myasthenia Gravis Activities of Daily Living (MG ADL) score was 5, and the Quantitative Myasthenia Gravis (QMG) score was 18 suggesting moderate severity. Respiration was poor with decreased breath-holding time (16 seconds); he exhibited marked orthopnea, along with difficulty in swallowing food in conjunction with nasal regurgitation of fluids. He could however maintain saturation above 95% on room air, with some use of accessory muscles of respiration. There were no features of cholinergic crisis. This presentation was suggestive of impending myasthenic crisis for which pyridostigmine doses were increased, mechanical ventilation support added, given intravenous immunoglobulin (IVIG) to which he responded in next two weeks. Rituximab was subsequently administered. By next 2 weeks, he tolerated spontaneous breathing trials through the tracheostomy tube and was transitioned to oral Mycophenolate Mofetil. Pyridostigmine was titrated to 60 mg every 3 hours, along with sustained release doses of 180 mg once daily. With these measures he recovered and could be deventilated in next three weeks and reached MG ADL score to 1. This case is simple yet complex and adequate history taking of self-dosing with inadequate doses of pyridostigmine helped to effectively optimise the drugs.

Case 2: Decades of Generalised Myasthenia Decoded-Slow Channel Congenital Myasthenic Syndrome (SCCMS)

A middle-aged female presented with insidious-onset, progressively worsening asymmetrical ptosis, bilateral external ophthalmoplegia, and proximal limb weakness from the first decade of her life with significant worsening from the last two years which were manageable as they did not interfere with her routine activities. There was mild diurnal fluctuation and easy fatiguability. She denied any sensory deficits, cranial nerve involvement (other than ocular), or autonomic symptoms. A family history of similar symptoms in first-degree relatives was noted. Her routine blood workup, electrolytes, autoimmune markers, and paraneoplastic panels were unremarkable. Nerve conduction studies (NCS) of all four limbs were normal. Her brain and orbit imaging (MRI), chest X-ray and 2D echocardiogram were also within normal limits. With the history of first decade onset of mild manageable facio-ocular proximal limb weakness, we proceeded with the Ice Pack Test and Neostigmine Challenge Test that showed positive response, indicating a neuromuscular transmission disorder. A CT thorax ruled out thymoma or thymic hyperplasia. In view of long-standing childhood onset disease with a positive family history, a congenital variant of myasthenia was suspected, and so Whole Exome Sequencing (WES) was done which revealed a pathogenic variant in the AChR gene consistent with slow-channel congenital myasthenic syndrome (CMS)4a. Gene: CHRNE (cholinergic receptor nicotinic epsilon subunit) - Chromosome 17; Variant: c.601+1G>T (splice site mutation); Zygosity: Homozygous, confirming Autosomal Recessive, Slow-channel congenital myasthenic syndrome-4A, OMIM: #605809. She was continued on anticholinesterase therapy without adequate response and then switched to Salbutamol tablets, which is the drug of choice for slow-channel congenital myasthenic syndrome after which she showed marked improvement in her overall symptoms. This case of slow-channel congenital myasthenic syndrome (CMS) highlights the diagnostic dilemma posed by phenotypic overlap between autoimmune MG and genetic disorders of neuromuscular transmission. Related learning pearls are discussed below.

Case 3: Mystery of Chronic Progressive External Ophthalmoplegia (CPEO)

A 26-year-old male presented with a 6-year history of bilateral asymmetric ptosis (right > left) and progressive external ophthalmoplegia. His symptoms progressed for the initial 2 years and were static since then. There were no associated symptoms of diplopia, limb weakness, fatiguability, sensory deficits, or systemic illness. There was no cognitive impairment or bowel/bladder involvement. Clinical tests for MG, Ice Pack and Neostigmine challenge tests were negative. CECT (Contrast Enhanced Computed Tomography) thorax ruled out thymoma. Thyroid function was normal, and anti-TPO (Thyroid Peroxidase) antibodies were negative. Fundus examination showed peripheral retinal pigmentary degeneration. Visual evoked potentials (VEP) revealed prolonged P100 latencies. ECG showed left anterior hemiblock (LAHB). Arterial lactate was within normal limits. Nerve conduction studies showed normal values. Serum ACE was significantly elevated (98.2 U/L), raising suspicion of neurosarcoidosis. However, there was no radiologic evidence of hilar lymphadenopathy or CNS lesions on imaging. With these, probability of mitochondrial disease / CPEO were also kept, but with normal cognition and auditory functions. Brain and orbit imaging were suggestive of atrophy of all extra ocular muscles without evidence of any infiltrative orbital disease suggestive of a very long duration disease. His CSF analysis was normal including CSF/Seurm lactate ratio.

The patient did not respond to standard anti-myasthenic drugs combination of Pyridostigmine and Prednisolone. Given the lack of response, negative pharmacologic testing,

presence of pigmentary retinopathy, and cardiac conduction defects, mitochondrial cytopathy (CPEO/Kearns-Sayre Syndrome) was a likely differential with neurosarcoidosis a second possibility. However, there was no systemic or radiologic correlation. Serum AChR antibodies came out to be positive. Due to high sensitivity and specificity of a positive AChR antibody test, a final diagnosis of Chronic Ocular MG was made. Chronic untreated myasthenia gravis may appear as irreversible external ophthalmoparesis with atrophy and fibrosis of the extraocular muscles and late proximal muscle weakness.

Case 4 Decoding Glioma in Myasthenia Gravis

An elderly male with diagnosed myasthenia gravis (AChR antibody positive, thymoma negative) and co-morbidities of type 2 diabetes mellitus, and hypertension presented with sudden onset right-sided hemiparesis and aphasia. He was on Pyridostigmine and MMF (Mycophenolate Mofetil) since diagnosis with initial months with steroids therapy. There was no history of loss of consciousness, headache, seizures, cranial nerve involvement, or bladder/bowel disturbances. A cerebral vascular event was the first differential. An urgent NCCT head (images unavailable) revealed an ill-defined intra-axial lesion in the left frontoparietal lobe with peripheral enhancement, suggestive of an intracranial space-occupying lesion (ICSOL). Magnetic Resonance Imaging (MRI) of brain with contrast followed, which showed a large solid-cystic lesion with irregular rim enhancement and central necrosis, indicating a likely high-grade glioma (**Fig 1**- T1contrast). EEG was normal, and routine investigations revealed elevated inflammatory markers. Resection of the intracranial growth was done by neurosurgery team with left front-parieto-temporal (FTP) craniotomy and gross total resection. Histopathology of the mass revealed glioblastoma multiforme (WHO Grade IV) (images not available), with immunohistochemistry (GFAP, ATRX, IDH, P53, Ki67) advised for further categorization. Postoperatively, the patient suffered difficult weaning from the ventilator that required judicious selection of antibiotics, escalation of anti-myasthenic drugs with IVIG use. With these he responded and discharged in stable condition in next 3 weeks. Neurophysiotherapy continued with a plan for adjuvant chemoradiotherapy, follow-up imaging, and oncological consultation. Occurrence of ICSOL in a patient with MG on immunotherapy points towards a possibility of opportunistic infections related SOLs, malignant tumors like Primary CNS lymphoma as patient had long duration of MMF. These 4 cases are summarized in **table1** given below.

Table 1. Summary of the MG cases.

Category	Case 1	Case 2	Case 3	Case 4
Age/Sex	52/Male	62/Female	26/Male	64/Male
Initial Diagnosis	AChR antibody-positive generalized MG	Slow-Channel Congenital Myasthenic Syndrome (CMS)	Ocular MG (AChR-positive)	AChR-positive MG (thymoma negative) With ICSOL + comorbidities (DM, HTN)
Presentation	Progressive orthopnea, dysphagia, slurred speech, missed Pyridostigmine, recent LRTI	First decade onset Insidious asymmetric ptosis, ophthalmoplegia, proximal limb weakness, diurnal fluctuation, fatigability	Asymmetric bilateral ptosis, progressive external ophthalmoplegia, no limb weakness or fatigability	Sudden right hemiparesis, aphasia; no seizures or LOC
Key Clinical Features	MG crisis, reduced breath holding, severe bulbar weakness	Family history positive; mild bilateral hearing loss	No response to Neostigmine/Ice Pack; pigmentary retinopathy, conduction defect on ECG	Normal EEG; postoperative ventilatory difficulties; ICSOL
Diagnostic Tests	MG ADL score 5 → improved to 1; QMG 18; Anti-MuSK negative; ICU care, IVIG, Rituximab, later Mycophenolate	Positive Ice Pack and Neostigmine Challenge; Genetic testing confirmed AChR mutation	AChR antibody positive; Ice Pack & Neostigmine negative; Fundus: pigmentary changes; ECG LAHB; VEP delayed; Serum ACE elevated; MRI- EOM Atrophy, CSF Normal,	NCCT & MRI Brain: left frontoparietal ICSOL with rim enhancement; Histopathology: Glioblastoma
Imaging	Not specified	CT thorax: Lung fibrosis	None initially; pending brain MRI	MRI brain: solid-cystic lesion consistent with glioblastoma
Treatment	Pyridostigmine escalated; IVIG; Rituximab; Mycophenolate mofetil	Anticholinesterase therapy with Pyridostigmine & Gravitor; physiotherapy Salbutamol	Empiric Pyridostigmine + steroids (no response)	Surgery (gross total resection) followed by chemoradiotherapy planned; supportive care

Outcome at Discharge	Marked improvement, mild generalized weakness, decannulated, ambulatory	Clinical improvement; mild GI side effects of therapy; regular follow-up advised	Stable but unresolved; further confirmatory tests pending	Clinically improved, stable, planned ongoing oncological care
Learning Points	Optimization of anti cholinesterase dosing in crisis can reduce crisis risks.	Suspect CMS in atypical long duration mild disease with positive pedigree Non response to standard antimyesthenic agents. Appropriate drug for CMS	MG-like features can overlap with mitochondrial syndromes; antibody positivity may be the decider	MG patients on immunotherapy with neurological deficits may harbor neoplasms; paraneoplastic associations possible

Figure 1. T1 contrast study of Brain in Axial view showing an solid cystic lesion with irregularly thickened ring enhancing margins with pressure changes on the adjacent brain parenchyma.

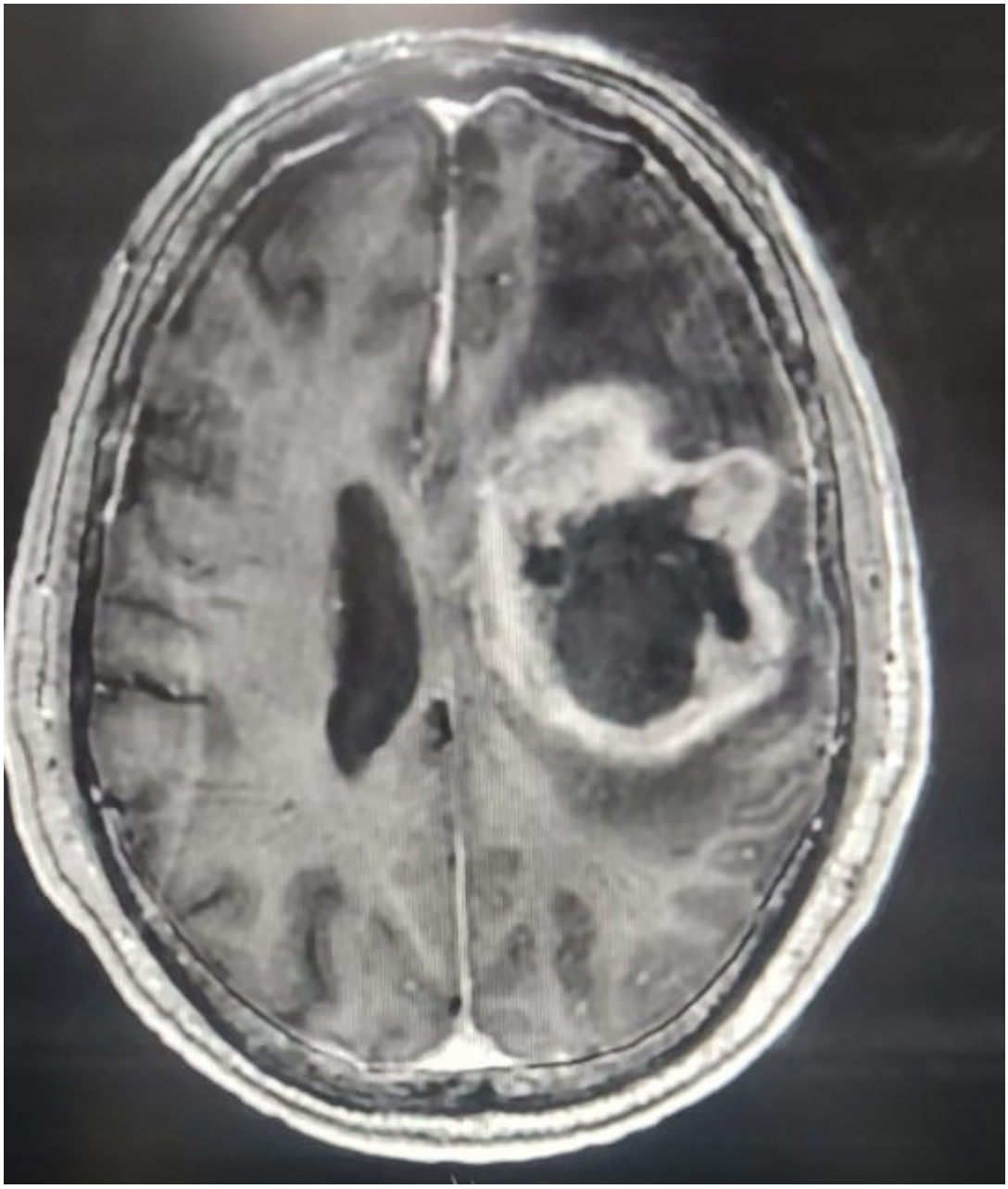

Implications

Case 1 of our series implies the importance of treatment related history taking skill that appear so subtle but can make a wide difference in decision while managing MG in critical phase. Combined with poor compliance, lack of knowledge and inadequate access to the field experts, the withdrawal or improper dosage of cholinesterase inhibitors (such as pyridostigmine) has devastating unforeseen course of the disease. Case 2 endorses that distinguishing CMS from autoimmune MG is critical, as immunotherapies are largely ineffective in CMS. The cornerstone of management is identification of CMS subtype and initiation of tailored disease modifying therapy; in this case salbutamol brought quick response. Case 3 had striking extra-ocular muscle atrophy in a seropositive MG that long duration undiagnosed course and poor response to immunotherapy and traditional medical management as disease process brought irreversible damage to the affected muscles. This case had unique clinical features mimicking mitochondrial disease. Case 4 prompted the authors to review the associations of MG with other extra-thymic malignancies; the details are discussed below.

DISCUSSION

Learning points from case 1 emphasizes that a subset of AChR antibody positive MG patients respond suboptimally to standard immunotherapy [5] and taking simple measures like upgrading Pyridostigmine dosing can be a successful oar to combat a crisis episode. A detailed history taking including drug dosage history as a protocol which becomes important in chronic neurological diseases where patients have often been found to be taking subnormal dosage of the prescribed medications citing the possibility of developing side effects and dependence without any objective scientific proof. This helped us to decide his maintenance plan of treatment and now the patient is doing well with optimized symptomatic drugs and immunotherapy. Counselling regarding drug doses also plays a vital role in adequate treatment. About 1/3 of MG patients have suboptimal response with adequate dosing. Interrupted and suboptimal pyridostigmine dosing is so frequently missed but easily rectifiable cause of myasthenic crisis (MC) in India where knowledge practice gap is wider added with limited socioeconomic resources.

Case 2 had clinical phenotype of facio-ocular weakness from the first decade that remained undiagnosed till sixth decade when began proximal suspicion of congenital myasthenia variant with a differential of mitochondrial disease, Chronic Progressive External Ophthalmoplegia (CPEO) were thought. Genetic sequences confirmed the CMS diagnosis. This rareness led to suspect variants of myasthenia like CMS. Poor response to standard anti-cholinesterase drugs (pyridostigmine) with long course of the illness without ever going in crisis were the atypical points for classic MG and led us to suspect congenital form of myasthenia. [6]. Finlayson et al. and Liewluck et al. reported that long-term treatment with oral salbutamol (a beta_2-adrenergic agonist) significantly improves muscle strength and stabilizes the clinical course in patients with SCCMS [7, 8]. While the exact mechanism is unknown, it is hypothesized that salbutamol stabilizes the postsynaptic membrane and may exert an anabolic effect on the neuromuscular junction, effectively counteracting the endplate damage caused by the "slow" channel kinetics.

The presence of family history, mild hearing deficits, and positive response to pharmacologic tests informed by genetic confirmation are all strong indicators of CMS. This case further demonstrates the need for heightened suspicion of CMS in patients showing inadequate or transient response to standard therapy. Atrophy of ocular muscles described as rare within the MUSK antibody positive subset [9]. Case 3 shows that classic seropositive MG, long duration and untreated can have severe atrophy of extra-ocular muscles which remains nonreversible with therapy. Structural atrophy in extraocular muscles signifies a severe and burnt-out stage of the diseased muscle. MG of Musk positive phenotype has prominent atrophy of the tongue and facial muscles without extraocular involvement. Radhakrishna Pedapati et al (2022) discussed atrophy mechanisms and stated that persistent low-grade inflammation may lead to motor endplate destruction resulting in the denervation and subsequent fibrosis of the affected muscles [10]. The diagnostic conundrum of chronic progressive external ophthalmoplegia (CPEO, a mitochondrial cytopathy) mimicking MG- compounded by positive AChR antibodies but negative pharmacologic testing- reflects a well-recognized but infrequent challenge in neuromuscular medicine. Overlap features such as ophthalmoplegia and ptosis necessitate a multidisciplinary and investigative approach, including antibody assays, imaging, and genetic/ metabolic studies. The co-occurrence of pigmentary retinopathy, cardiac conduction defects, and lack of immunotherapy response pivoted the diagnostic hypothesis away from MG towards mitochondrial disease and, less likely, neurosarcoidosis. Reports of secondary, non-pathogenic positivity for AChR antibodies in mitochondrial syndromes have been previously described and may confound diagnosis [11]. AChR antibody test is highly specific having methological impact with Radioimmunoprecipitation assays (RIPA) are standard, offering up to 98% specificity. Cell-based assays (CBA) provide high specificity (97.8%–100%) for generalized MG [12]. This case is rare and interesting as AChR positive MG with Ocular muscle atrophy has not been reported so far at best of author's knowledge [13, 14]. Patients on long use of MMF can present with ICSOL described in case report by Dasgupta et al. in 2005[15]. Our patient revealed glioblastoma which is reported more in immunocompromised renal

transplant patients but not in MG patients with MMF [16]. Paraneoplastic association of MG with Glioblastoma is also a possibility as speculated in the report by Slegers et al in 2022 wherein a case was described which suggested that MG may potentially act as a paraneoplastic phenomenon of primary brain tumors [17].

Similarly, Khateb et al. (2024) carried out a retrospective study of 436 patients which suggested that Myasthenia Gravis (MG) may behave as a paraneoplastic disorder for extrathymic malignancies. MG patients exhibited a significantly higher cancer rate (32%) compared to controls, with a nearly threefold relative risk compared to rheumatology patients. Notably, cancer prevalence peaked within a ±5-year "paraneoplastic window" relative to MG onset, emphasizing the need for systemic cancer screening in MG [18]. The weaning issue in MG in perioperative period is also a matter of concern that require optimal anti-myasthenic drugs with steroid cover till the weaning is complete and at the same time adequate permissible antibiotics to combat likely infection during that period. While rare, the co-occurrence could be a paraneoplastic phenomenon, though not currently defined as such in diagnostic criteria.

Treatment with corticosteroids for MG may affect overall survival in glioblastoma patients. Glioblastoma involves an immunosuppressive environment, and some therapies targeting it (like temozolomide) are used, but they are not standard causes of MG. This case involving the discovery of a high-grade glioma in a patient with MG, raises important considerations for clinicians managing chronic immunosuppressed patients presenting with new neurological deficits. The differential diagnosis of intracranial space-occupying lesions (ICSOL) in such patients must remain broad, accounting for opportunistic infections, neoplasms, and, rarely, paraneoplastic syndromes, as discussed above. The relationship between MG and CNS neoplasms such as glioblastoma is not well-established, though rare paraneoplastic associations have been reported.

CONCLUSION

Myasthenia Gravis (MG) exemplifies a complex and evolving field in autoimmune neuromuscular diagnosis and management, as illustrated by the heterogeneity of presentations and diagnostic challenges observed in this case series. Our case series evidences the spectrum of MG and its mimics, emphasizing the importance of early and accurate diagnosis using a combination of clinical, serological, neurophysiological, and genetic tools; timely, individualized immunomodulation, especially in crisis or refractory states; vigilance for congenital, genetic, and mitochondrial mimics or overlaps—prompting withdrawal of ineffective immunotherapies in favor of tailored approaches; close monitoring for complications (including opportunistic infections and neoplasia), especially in the context of chronic immunosuppression. Ultimately, management of myasthenic syndromes remains anchored by multidisciplinary collaboration and evolving diagnostic-therapeutic algorithms, informed by advances in genomics, targeted therapies, and case-based learning.

Ethical Statement

Written informed consent was obtained from the patients.

Acknowledgments

This case series is an original work and addresses an important clinical question in field/subspecialty and, we believe, offers findings of relevance to your readership. The manuscript is original, has not been published previously, and is not under consideration elsewhere. All authors have approved the final version and agree with its submission to your journal. We gratefully acknowledge the entire study team, the hospital staff, and, above all, the patients and their relatives, whose participation and trust made this research possible.

Conflicts of Interest

No conflicts of interest to be declared by the authors.

Abbreviations

MG- Myasthenia Gravis
AChR- Acetylcholine receptor
MuSK- Muscle-specific kinase
IVIG- Intravenous immunoglobulins
LRTI- lower respiratory tract infection
AIIMS- All India Institute Of Medical Sciences
MG ADL- Myasthenia Gravis Activities of Daily Living
QMG- Quantitative Myasthenia Gravis
MC- Myasthenic crisis
NCS-Nerve conduction studies
MRI- Magnetic Resonance Imaging
CT- Computed Tomogram
WES- Whole Exome Sequencing
CMS4a- Congenital myasthenic syndrome
CPEO- Chronic Progressive External Ophthalmoplegia
VEP- Visual evoked potentials
ECG- Electrocardiography
LAHB- left anterior hemiblock
TPO- Thyroid Peroxidase
Angiotensin converting enzyme-ACE
CSF- cerebro spinal fluid
RIPA- Radioimmunoprecipitation assays
CBA- Cell-based assays
MMF- Mycophenolate Mofetil
NCCT- non contrast computed tomogram
ICSOL- space-occupying lesion
EEG- Electroencephalography
FTP- front-parieto-temporal
WHO- World Health Organization

REFERENCES

1. Gilhus NE, Tzartos S, Evoli A, Palace J, Burns TM, Verschuuren JJGM. Myasthenia gravis. Nat Rev Dis Primers. 2019;5(1):30

2. Meriggioli MN, Sanders DB. Autoimmune myasthenia gravis: emerging clinical and biological heterogeneity. Lancet Neurol. 2009 May;8(5):475-90. doi: 10.1016/S1474-4422(09)70063-8. PMID: 19375665; PMCID: PMC2730933.

3. Narayanaswami P, Sanders DB, Wolfe G, et al. International Consensus Guidance for Management of Myasthenia Gravis: 2020 Update. Neurology. 2021;96(3):114-22.

4. Farmakidis C, Pasnoor M, Dimachkie MM, Barohn RJ. Treatment of Myasthenia Gravis. Neurol Clin. 2018;36(2):311-37.

5. Feng X, Song Z, Wu M, Liu Y, Luo S, Zhao C, Zhang W. Efficacy and Safety of Immunotherapies in Refractory Myasthenia Gravis: A Systematic Review and Meta-Analysis. Front Neurol. 2021 Dec 1;12:725700. doi: 10.3389/fneur.2021.725700. PMID: 34925206; PMCID: PMC8672452.

6. Karimi N, Ghasemi A, Panahi A, Ziaadini B, Nafissi S. CHRNE-related congenital myasthenic syndrome in Iran: Clinical and molecular insights. Neuromuscul Disord. 2025 Jan;46:105234. doi: 10.1016/j.nmd.2024.105234. Epub 2024 Oct 25. PMID: 39550999.

7. Finlayson S, Beeson D, Palace J. Salbutamol and ephedrine in the treatment of congenital myasthenic syndromes. J Neurol. 2011;258(11):1956-65.

8. Liewluck T, Selcen D, Engel AG. Beneficial effects of albuterol in congenital myasthenic syndromes. Muscle Nerve. 2011;44(5):789-94

9. Gratton SM, Herro A, Bermudez-Magner J, Guy J. Atrophy and Fibrosis of Extra-Ocular Muscles in Anti-Acetylcholine Receptor Antibody Myasthenia Gravis. Open Journal of Ophthalmology. 2014;4:117-119

10. Pedapati R, Ravishankar U, Hazeena P, Shanmugam S, Chandrasekharan A, Venkatasubramanian S. Extraocular muscle atrophy in myasthenia gravis. Ann Indian Acad Neurol. 2014;17(4):445-7. doi: 10.4103/0972-2327.144028

11. Maddison P, Sadalage G, Ambrose PA, Jacob S, Vincent A. False-positive acetylcholine receptor antibody results in patients without myasthenia gravis. J Neuroimmunol. 2019 Jul 15;332:69-72. doi: 10.1016/j.jneuroim.2019.04.001. Epub 2019 Apr 3. PMID: 30959340

12. Mirian A, Nicolle MW, Edmond P, Budhram A. Comparison of fixed cell-based assay to radioimmunoprecipitation assay for acetylcholine receptor antibody detection in myasthenia gravis. J Neurol Sci. 2022 Jan 15;432:120084. doi: 10.1016/j.jns.2021.120084. Epub 2021 Dec 8. PMID: 34906880

13. Chan JW, Orrison WW. Ocular myasthenia: a rare presentation with MuSK antibody and bilateral extraocular muscle atrophy. Br J Ophthalmol. 2007 Jun;91(6):842-3. doi: 10.1136/bjo.2006.108498. PMID: 17510484; PMCID: PMC1955582.

14. Ricciardi D, Todisco V, Tedeschi G, Cirillo G. Anti-MuSK ocular myasthenia with extrinsic ocular muscle atrophy: a new clinical phenotype? Neurol Sci. 2020 Jan;41(1):221-223. doi: 10.1007/s10072-019-04038-4. Epub 2019 Aug 17. PMID: 31422505.

15. Dasgupta N, Gelber AC, Racke F, Fine DM. Central nervous system lymphoma associated with mycophenolate mofetil in lupus nephritis. Lupus. 2005;14(11):910-3. doi: 10.1191/0961203303lu2179cr. PMID: 16335585.

16. Saidi, I. , Benbella, M. , Benamar, L. , Ouzeddoun, N. and Bouattar, T. (2024) Cerebral Glioblastoma in Renal Transplant Recipient: A Case Report. Open Journal of Nephrology, 14, 10-16. doi: 10.4236/ojneph.2024.141002.

17. Slegers RJ, Bouwens van der Vlis TAM, Ackermans L, Hoeben A, Postma AA, Compter I, et al. Myasthenia gravis after glioblastoma resection: paraneoplastic syndrome or coincidence? A unique case report and review of the literature. J Neurol. 2022 Mar;269(3):1653-6

18. Khateb M, Abu Zant M, Bsoul A, Karny T, Yarnitsky D, Shelly S. The association between myasthenia gravis and higher extrathymic cancer risk. Brain Behav. 2025 Jan;15(1):e70143. doi: 10.1002/brb3.70143